



Striae distensae treatment with autologous lipotransfer and needling: Clinical and histological analysis: A pilot study

Chang Yung Chia¹, Patrícia Ritter², Tamsin A Burgues³

¹ Member of the Brazilian Society of Plastic Surgeons; Chief Surgeon of Reconstructive Microsurgery Department of Hospital dos Servidores do Estado do Rio de Janeiro, Brazil

² Member of the Brazilian Society of Plastic Surgeons, Brazil

³ Resident at the Ivo Pitanguy Institute, Santa Casa de Misericórdia Hospital in Rio de Janeiro, Brazil; Bachelor of Medicine and Bachelor of Surgery (MBBS) from Norwich Medical School, Norfolk, England

Abstract

Striae Distensae is characterized by skin atrophy and there is no successful treatment that promotes its regeneration. Fat grafting has been used with positive results in volume augmentation and tissue regeneration, based on its content of mesenchymal cells. The authors studied tissue regeneration with autologous lipoaspirate graft, needling and both techniques combined, as well as compared four lipoaspirate processing methods. Clinical and histological evaluation was accomplished. The best clinical outcome was obtained by lipoaspirate graft and needling combined, while needling alone and grafting alone had no clinically significant improvement.

Keywords: striae distensae, regeneration, autologous fat grafting, adipose tissue, stem cell

Introduction

Striae Distensae (SD) are linear and depressed skin deformities of varied length and width, caused by atrophic changes in dermis and epidermis [1]. It is a very common cosmetic problem, which can cause significant psychological distress for patients [2]. It is two and a half times more frequent in women, and affects up to 90% of pregnant women. SD usually appear in puberty, obesity, pregnancy, elevated serum level of steroid hormones (endogenous or exogenous), and in metabolic disorders [6, 11]. They normally develop on the abdomen, breasts, lower back, buttocks and thighs. Endocrine and metabolic factors are listed as important causes, but the etiology is not completely understood. SD show atrophic and degenerative characteristics under histological, biochemical and immunological analysis. The dermis and epidermis are thinned, the rete ridges in the dermal-epidermal junction are flattened, and there is a decrease in quantity and quality of fibroblasts, collagen and elastic fibers and extracellular matrix [1, 5]. Until the present time there is no treatment that effectively regenerates the atrophied tissues [12].

Autologous fat transfer is being widely used in both aesthetic and reconstructive surgery to provide volume augmentation and tissue regeneration [13]. It is, in many cases, the first treatment option for radiodermatitis, breast reconstruction, congenital lipodystrophy, cutaneous fistulas and ulcers, chronic scars, Dupuytren's contracture, among other disorders [14, 15]. The mesenchymal stem cells (MSC) present in subcutaneous adipose tissue are probably responsible for its regeneration ability. The recent debate regarding fat grafting concerns how the different processing methods of the lipoaspirate may influence the therapeutic effect, and if it is necessary to associate additional growth factors. This evidence, however, is currently based on clinical observations, in vitro or animal experiments [16, 17].

The clinical and histological correlation of cutaneous regeneration in humans has not yet been done [18, 23].

The present pilot study aims to evaluate the regeneration ability of the autologous lipoaspirate graft in atrophic skin lesions, represented by Striae Distensae, and to correlate clinical to histological changes. At the same time, to verify what would be the best processing method of the lipoaspirate, and whether it is necessary to associate another procedure to stimulate local growth factor release (to activate a regenerative response), represented by needling [24, 26].

Method

The research was performed in accordance with the Declaration of Helsinki. This is a prospective pilot study, an intra-individual comparison, with two female patients. The first patient is a 19-year-old nulliparous female, with atrophic cutaneous SD since puberty. During aesthetic liposuction surgery, four lesions were selected on the iliac region and numbered from 1 to 4. On lesions 1 and 2, autologous lipoaspirate was injected intradermally and subdermally. Lesions 3 and 4 were not treated. Lesion 1 was also needled up to the subcutaneous (Fig1).

The second patient is a 23-year-old female who had suffered stretch marks since puberty which worsened during pregnancy. During aesthetic liposuction, ten similar lesions were selected in the infra-umbilical region. Eight of them were divided into four groups of 2 lesions. Each group had a different method of lipoaspirate processing, which were centrifugation, decantation, washing, and wiping. Both lesions were grafted, but only one was also needled. Lesion number 5 was needled only and number ten was left untouched for comparison (figure 2). Three months after this treatment, patient 2 was submitted to elective abdominoplasty and Striae Distensae were resected for

histological analysis (table 1). Patient 1 was submitted to clinical observation only.

Table 1: Study design for comparison of fat processing methods.

Striae #	Fat processing mode
Striae 1	Centrifuged fat
Striae 2	Centrifuged fat + needling
Striae 3	Decanted fat
Striae 4	Decanted fat + needling
Striae 5	Needling
Striae 6	Washed fat
Striae 7	Washed fat + needling
Striae 8	Wiped fat
Striae 9	Wiped fat + needling
Striae 10	Control – untreated striae

Striae Distensae Treatment

Lipoaspirate was obtained under general anesthesia, with infiltration of saline solution with lidocaine at 0, 5% and adrenaline at 1:250.000 concentration. The liposuction cannula was 3mm in internal diameter with three sequential holes, attached to a 60cc syringe. Fifty milliliters of aspirate were processed in each of four ways: centrifuged (3.000 rpm for 3 minutes in a Technofat centrifuge, according to Coleman’s technique, the “pellet”, however, was collected along with adipocytes); decanted (by gravity inside the syringe until three phases were distinguished); washed (by adding 0,9% saline solution at a 1:1 ratio and phases separation by decantation twice); or “wiped” (aspirate was spread in a surgical gauze and excess fluids were removed). Processed lipoaspirate was injected with an 18G needle into the depressed lesion in dermal and subdermal layers, through retroinjection, with a moderate overcorrection. Needling was made with a 26G needle, perpendicular to the skin, through all skin layers until the injected lipoaspirate was reached. An antibiotic ointment was used for 48 hours.

Clinical Evaluation

Patient 1 was examined monthly until the sixth month and the visual aspect of the lesions was subjectively evaluated (epidermal transparency, vascularization, and similarity to the adjacent healthy skin), lesion-skin leveling was assessed by palpation. Patient 2 was followed up clinically until the third month, when she underwent an abdominoplasty and the SD were resected and sent for histological analysis.

Histological Evaluation

Each lesion was resected including the normal skin around it and the subcutaneous tissue. Samples were fixated in formaldehyde and sectioned perpendicular to the striae’s long axis also containing surrounding healthy skin and subcutaneous tissue. Picrosirius red (PS) was used to visualize collagen fibers, Alcian Blue (AB), for the extracellular matrix, Orcein (Orc) for elastic fibers, Orcein after oxidation (OxOr) for newly formed elastic fibers, and haematoxylin and eosin (H&E) under high magnification for fibroblasts morphometry.

Results

Clinical Results

On both patients, SD treated by lipoaspirate grafting associated with needling maintained 70% to 90% of grafted volume, assessed by palpation. The ones treated by grafting alone retained minimal or no graft volume. The lesion

treated by needling alone (on the second patient) had no change in the furrow.

The visual aspect of the grafted and needled SD showed a subtle vascularization improvement, better similarity to the surrounding skin and some reduction in the width. Superior clinical results were observed in SD treated by the lipoaspirate processed through decantation and centrifugation; the ones treated by washed and wiped lipoaspirate showed insignificant changes. SD treated by grafting alone or needling alone showed no visual improvement as compared to the control lesion.

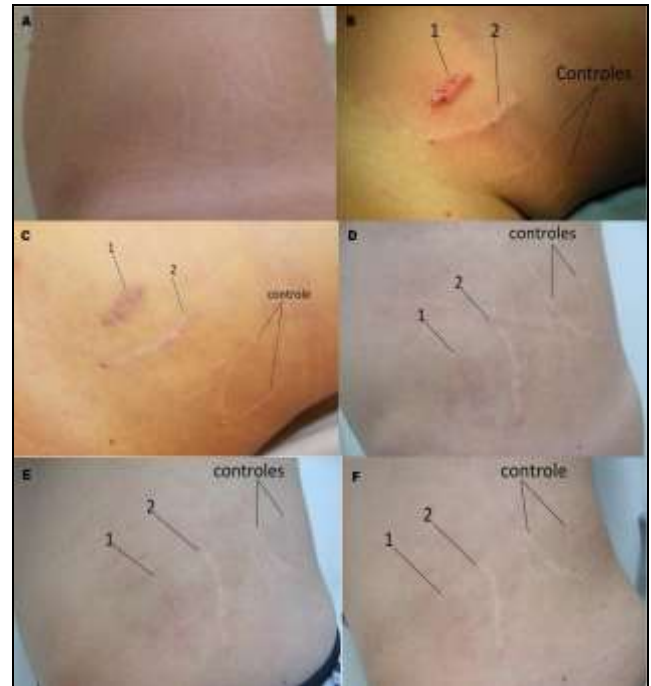

Fig 1: Patient 1. (A) Pre-operative; (B) Immediate post-operative: SD 1 – fat graft and needling, SD 2 – fat graft, SD 3 and 4 – controls; (C) 9 days post-op; (D) 28 days post-op; (E) 103 days post-op; (F) 163 days post-op.

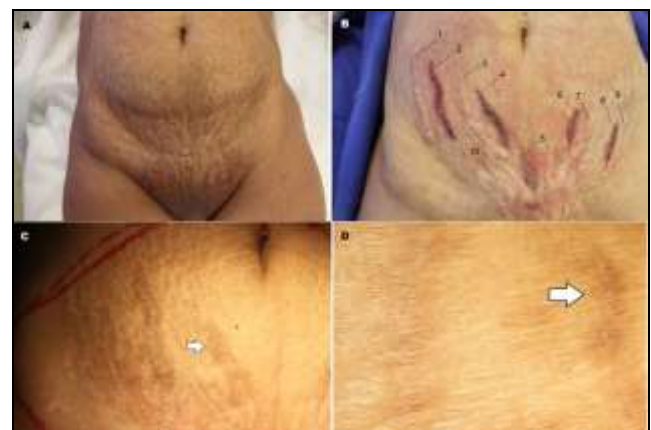

Fig 2: Patient 2. (A) Pre-operative; (B) Immediate post-operative; (C) 3 months post-op, before abdominoplasty, observe the better clinical outcome of SD 4; (D) Detail.

Histology

SD treated by needling alone showed no changes in epidermis or dermoepidermal junction (DEJ). There was an improvement in collagen fibers condensation, without concomitant Glycosaminoglycans (GAGs) improvement. There was also no formation of new elastic fibers (fig. 3B, 4B, 5B, 6B and 7B).

There was a discrete improvement in the epidermal layer and the DEJ, increased condensation of collagen fibers in the dermis with concomitant increase in the GAGs, and appearance of some elaunin and oxytalan elastic fibers, in SD treated with lipoaspirate graft alone (fig. 3C, 4C, 5C, 6C and 7C).

SD treated by lipoaspirate graft and needling combined, showed epidermal thickening and DEJ rete ridges intensification, as there was a significant increase of collagen fibers and GAGs, and also a higher incidence of newly formed oxytalan elastic fibers (fig. 3D, 4D, 5D, 6D and 7D).

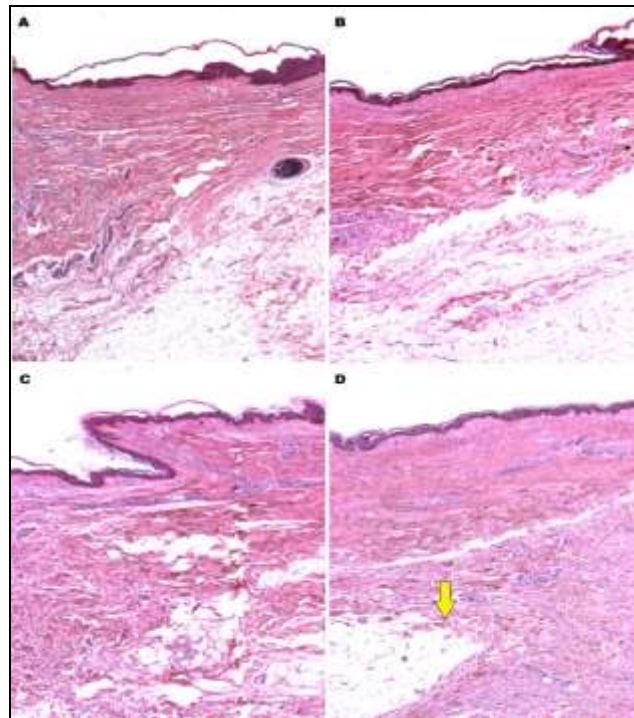


Fig 3: Hematoxylin-Eosin stained. (A) Normal skin. (B) SD treated with needling only. (C) SD treated with fat graft only. (D) SD treated with fat graft and needling combined. Note the lasting grafted fat 3 months after dermal injection.

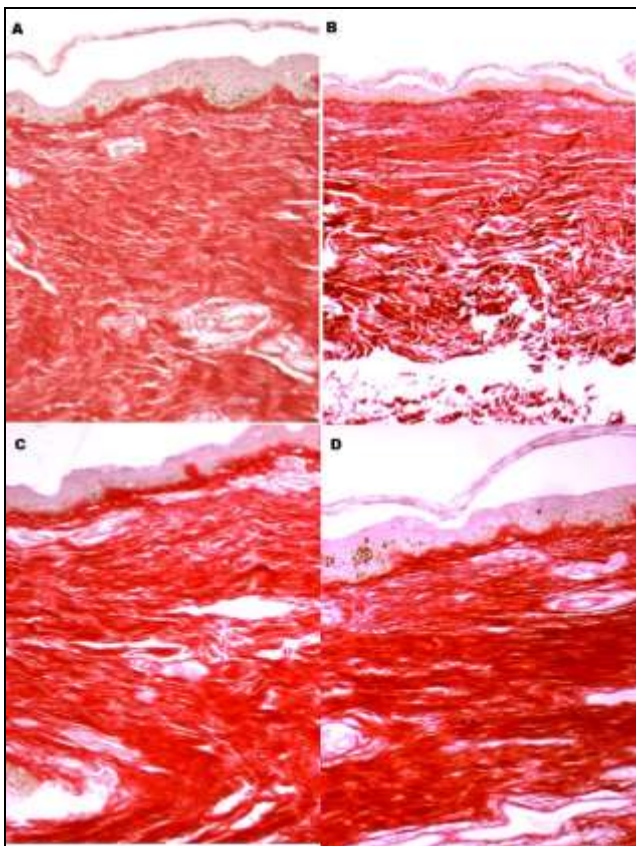


Fig 4: Picosirius colored collagen fibers in red. (A) Normal skin. (B) Striae treated with needling only. (C) Striae treated with fat graft only. (D) SD treated with fat graft and needling combined.

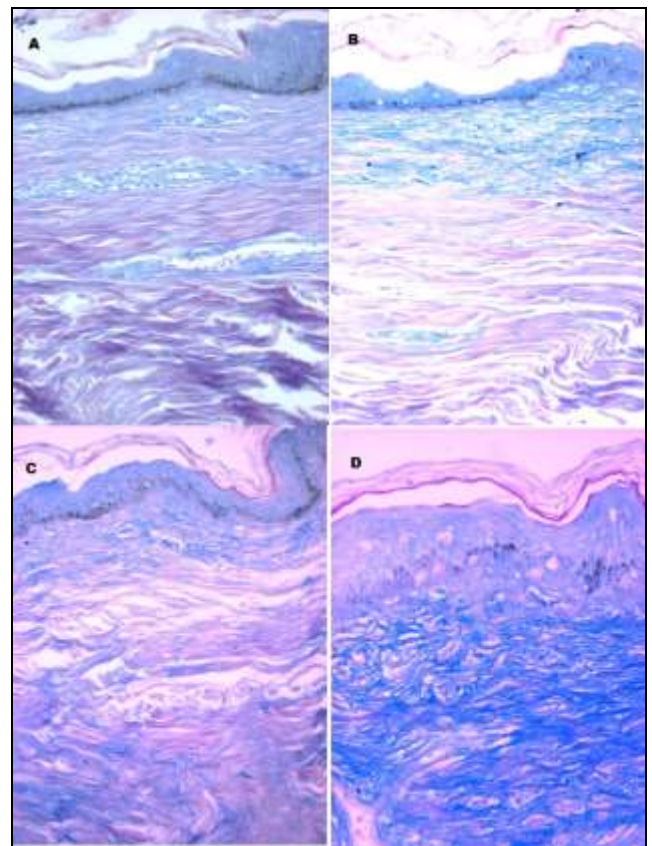


Fig 5: Alcian Blue colored GAGs in blue. (A) Normal skin. (B) SD treated with needling only. (C) SD treated with fat graft only. (D) SD treated with fat graft and needling combined.

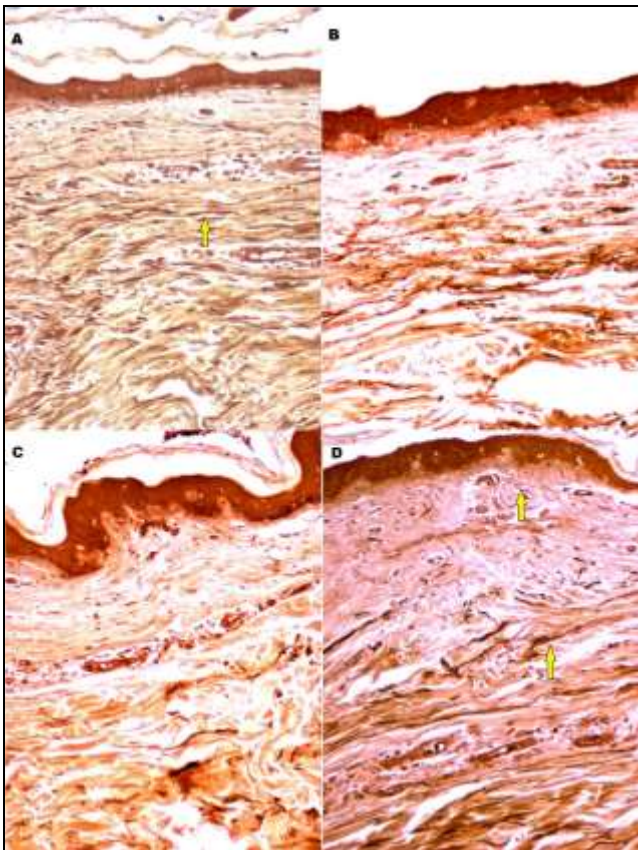


Fig 6: Orcein. (A) Normal skin. (B) SD treated with needling only. (C) SD treated with fat graft only. (D) SD treated with fat graft and needling combined. Elastic fibers (arrows) are colored in dark brown.

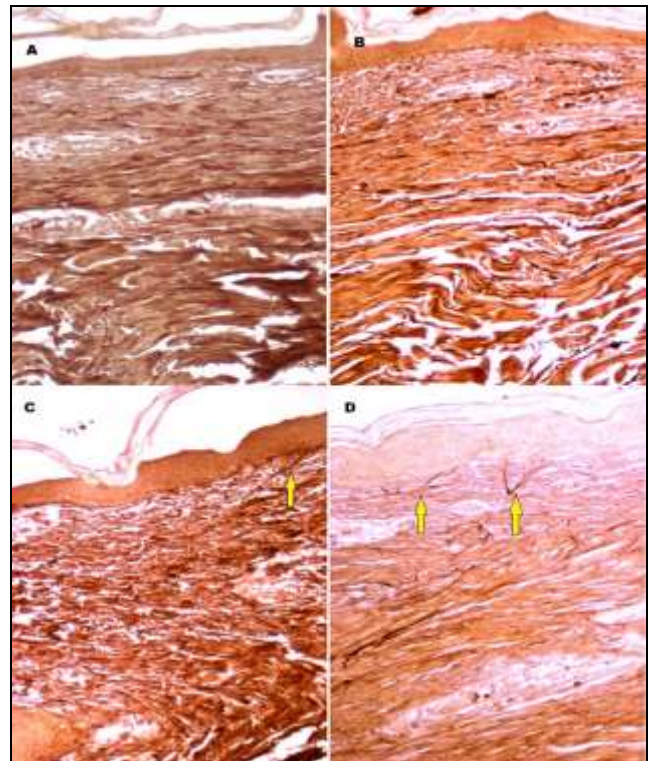
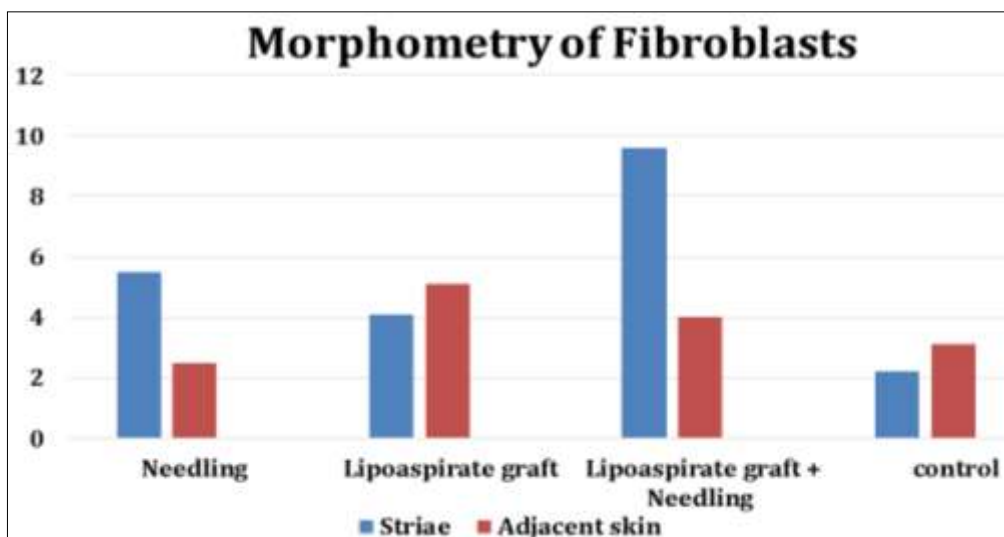


Fig 7: Oxidized Orcein. (A) Normal skin. (B) SD treated with needling only. (C) SD treated with fat graft only. (D) SD treated with fat graft and needling combined. Newly formed oxytalan elastic fibers (arrows).

Morphometrically, there was a statistically significant increase ($p < 0.0001$) in fibroblasts in SD treated with lipoaspirate graft and needling combined (graphic 1).



Graphic 1: Comparison of fibroblasts number by field of view (40x magnification) in the treated SD, in adjacent skin, and in the untreated SD.

Discussion

In addition to physical protection and thermal regulation, skin is also involved in neurological, immune, endocrine, metabolic and regenerative functions. It is one of the most active, continually renewed, and easily accessed organs. And because of its location, Striae Distensae can be easily used as an experimental model to help us understand the mechanisms of tissue regeneration. Likewise, the adipose tissue is not only an energy reservoir

and thermal isolator. It is part of the endocrine and immune systems as it secretes and converts hormones, growth factors, enzymes, cytokines, factors of the complement system and proteins. It participates in coagulation, appetite, feeding behavior, body weight regulation, immunity, glucose and lipid metabolism, reproduction, angiogenesis, fibrinolysis and vascular tonus. Adipose tissue holds adipocytes along with other important cells of the adipose-derived stromal vascular fraction (SVF),

which contains hematopoietic cells, endothelial cells, pericytes and adipose precursor cells. All these cells are grafted along with the lipoaspirate, and they are essential for graft survival and renewal.

The lipoaspirate graft technique has been used in tissue repair, chronic inflammation, and even new tissue formation, acting as an "anti-fibrotic" and "regenerating" mediator. The MSC, however, need a trigger to start and guide this regenerative process (substances released by the injured tissue). Innumerable substances, including growth factors and hormones, have been identified, but how they act, interact with each other, and with cells and tissues, still remains unknown. Platelet rich plasma (PRP) and platelet rich fibrin (PRF) have been used alone or combined with SVF or MSC grafts to activate or potentiate their action. Another way to stimulate regeneration is by creating a chemical, physical or mechanical minor local traumatic stimulus. Camirand described in 1997 needle dermabrasion, after he noticed an improvement in pigmentation and vascularization, in hypopigmented and fibrotic scars submitted to tattoos. Since then, needle dermabrasion has been used in scar treatment. More recently, the same knowledge was used in aesthetic treatments, with the advantage of deep dermal stimulation, without epidermal removal or its basal layer lesion, as happens with ablative laser and chemical peelings.

The present study investigated atrophic skin regeneration, promoted by autologous lipoaspirate graft in SD, and compared the effects of lipoaspirate graft alone, needling alone and lipoaspirate graft and needling combined, to an untreated lesion. Four lipoaspirate processing methods were also compared. The decanted and the centrifuged lipoaspirate grafts (including pellet) showed significantly superior clinical results than the washed and the wiped.

It is not possible, though, to make conclusions on the lipoaspirate processing method, because of the reduced sample (n=1), the lack of histological analysis (quality, quantity and cell viability) and biochemical analysis (quality and quantity of humoral factors) of the graft content. The SD grafted with decanted lipoaspirate had the best clinical outcome, so it was the only one studied further. Needling alone caused collagen quantity enhancement in the papillary dermis, without a concomitant increase in the GAGs, resulting in a fibrotic scar. This probably happened because the atrophic skin lacks cellular elements necessary for good healing, so the traumatic stimulus alone triggered a mild scar formation process. Lipoaspirate graft alone promoted modest tissue regeneration, perhaps because cellular signaling was lacking. Lipoaspirate graft and needling combined led to epidermal thickening and dermoepidermal papillae restoration, with concomitant collagen fibers and increase in the GAGs. This included the appearance of newly formed elauninic and oxytalan elastic fibers, which are characteristic of tissue "regeneration". Additionally, there was the statistically significant increase in fibroblast when compared to lipoaspirate graft alone, needling alone, and to untreated SD. The lipoaspirate graft was organized and stable in the reticular dermis, three months after treatment. These findings suggest that stimulating or trigger elements are as important as the presence of mesenchymal stromal cells. The regeneration stimuli must be created (placing MSC) and "guided" (minor controlled trauma) to the injured tissue. An isolated traumatic stimulus applied to the atrophic tissue (needling) resulted in an increase of scar

fibrosis.

The lipoaspirate grafted progenitor cells seem to have responded to liposuction trauma mediators, and the graft maintained its volume in place, without, however, extending its regeneration action to neighboring tissues. SD was in a stable atrophic stage. When both stimuli were combined, the progenitor mesenchymal cells (from the graft) received damaged tissue signaling, activating and guiding the regeneration process to the cutaneous striae.

Conclusion

The regeneration action of the lipoaspirate graft is based on tissue engineering, in which interaction between progenitor cells, an extracellular matrix and a trigger is necessary. The present pilot study suggests that the humoral factors released by injured tissue act as a trigger to activate and guide the regenerative reaction to the site of injury. The processing method of the lipoaspirate may influence its biological behavior. Prospective studies are suggested for a better understanding of this issue.

References

1. Zheng P, Lavker RM, Kligman AM. Anatomy of striae. *British Journal of Dermatology*. 1985; 112:185-193.
2. Arem AJ, Kischer CW. Analysis of Striae. *Plast Reconst Surg*. 1980; 65(1):22-29.
3. Watson REB, Parry EJ, Humphries JD. Fibrillin Microfibrils are reduced in skin exhibiting striae distensae. *British Journal of Dermatology*. 1998; 138:931-937.
4. Mitts TF, Jimenez F, Hinek A. Skin Biopsy Analysis Reveals Predisposition to Stretch Mark Formation. *Aesthetic Surgery Journal*, 2009, 593-600.
5. Cordeiro RCT, Zecchin KG, Moraes AM. Expression of estrogen, androgen, and glucocorticoid receptors in recent Distensae. *International Journal of Dermatology*. 2010; 49:30-32.
6. Wollina U, Pabst J, Schönlebe J, Abdel-Naser MB, Konrad H, *et al*. Side-effects of topical androgenic and anabolic substances and steroids. A short review. *Acta Dermatoven APA*. 2007; 16(3):117-22
7. Rogalski C, Haustein UF, Glander HJ, Paasch U. Extensive Striae Distensae as a result of Topical Corticosteroid Therapy in Psoriasis Vulgaris. *Acta Derm Venereol*. 2008; 83:54-5
8. Rotsztejn H, Juchniewicz B, Nadolski M. The unusually large striae distensae all over the body. *Advances in Medical Sciences*. 2010; 55(2):343-345.
9. Yosipovitch G, DeVore A, Dawn A. Obesity and the skin: Skin physiology and skin manifestations of obesity. *J Am Acad Dermatol*. 2007; 56(6):901-920.
10. Hidalgo LG. Dermatological Complications of Obesity. *Am J Clin Dermatol*. 2002; 3(7):497-506
11. Larsson P-A, Lidén S. Prevalence of Skin Diseases among adolescents 12-16 years of age. *Acta Dermatovener (Stockholm)*. 1980; 60:415-23
12. Elsaie ML, Baumann LS, Elsaie LT. Striae Distensae (Stretch Marks) and Different Modalities of Therapy: Na Update. *Dermatol Surg*. 2009; 35:563-73
13. Blandton MW, Hadad I, Johnstone BH. Adipose Stromal Cells and Platelet-Rich Plasma Therapies Synergistically Increase Revascularization during Wound Healing. *Plast Reconst Surg*. 2009; 123(5):56S-64S.

14. Hanson SE, Bentz ML, Hematti P. Mesenchymal Stem Cell Therapy for Nonhealing Cutaneous Wounds. *Plast Reconstr Surg.* 2010; 125(2):510-516.
15. Ko SH, Nauta A, Wong V. The Role of Stem Cells in Cutaneous Wound Healing: What Do We Really Know? *Plast Reconstr Surg.* 2011; 127(1S):10S-20S.
16. Mojallal A, Lequex C, Shipkov C. Improvement of Skin Quality after Fat Grafting: Clinical Observation and an Animal Study. *Plast Reconstr Surg.* 2009; 124(3):765-774.
17. Marra KG, DeFail AJ, Clavijo-Alvarez JA. FGF-2 Enhances Vascularization for Adipose Tissue Engineering. *Plast Reconstr Surg.* 2008; 121(4):1153-1164.
18. Coleman SR. Structural Fat Grafting: More Than a Permanent Filler. *Plast Reconstr Surg.* 2006; 118(3S):108S-120S.
19. Rigotti G, Marchi A, Galiè M, *et al.* Clinical Treatment of Radiotherapy Tissue Damage by Lipoaspirate Transplant: A Healing Process Mediated by Adipose-Derived Adult Stem Cells. *Plast Reconstr Surg.* 2007; 119(5):1409-22
20. Lolli P, Malleo P, Rigotti G. Treatment of Chronic Anal Fissures and Associated Stenosis by Autologous Adipose Tissue Transplant: A Pilot Study. *Dis Colon Rectum.* 2010; 53:460-66
21. Suga H, Eto H, Aoi N. Adipose Tissue Remodeling under Ischemia: Death of Adipocytes and Activation of Stem Progenitor Cells. *Plast Reconstr Surg.* 2010; 126(6):1911-1923.
22. Eto H, Kato H, Suga H, Aoi N, Doi K, Kuno S, Yoshimura K. The Fate of Adipocytes after Nonvascularized Fat Grafting: Evidence of Early Death and Replacement of Adipocytes. *Plast Reconstr Surg.* 2012; 129(5):1081-92
23. Schipper BM, Marra KG, Zhang W, Donnenberg AD, Rubin JP. Regional Anatomic and Age Effects on Cell Function of Human Adipose-Derived Stem Cells. *Ann Plast Surg.* 2008; 60(5):538-44
24. Aus MC, Fernandes D, Kolokythas P, Kaplan HM, Vogt PM. Collagen induction therapy: An alternative treatment for scars, wrinkles and skin laxity. *Plast Reconstr Surg.* 2008; 121:1421.
25. Aus CM, Reimers K, Repenning C, Stahl F, Jahn S, Guggenheim M, Schwaiger N, Gohritz A, Vogt PM. Percutaneous collagen induction: minimally invasive skin rejuvenation without risk of hyperpigmentation – fact or fiction? *Plast Reconstr Surg.* 2008; 112(5):1553-1563.
26. Camirand A, Doucet J. Needle dermabrasion. *Aesthetic Plast Surg.* 1997; 21:48